

DISCHARGE SUMMARY

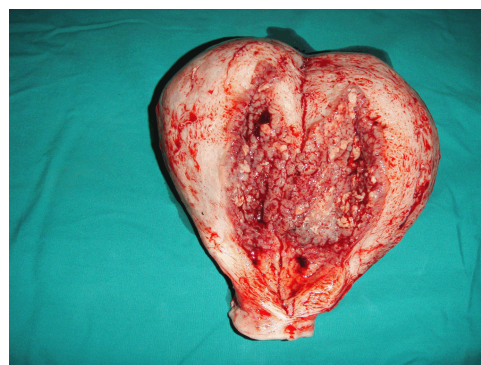
Reg. No. : 18926 **Date** : 15-Sep-2018
Name : Minal J Kalawadiya **Age** : 31.0 **BG Rh** :
City : **DOA** : 01-May-2018 **DOD** :

Condition on Admission :

Menorrhagia not relived by Medical Rx
Pt of Thyroid
On Tab Thyrox (100) od

Progress in hospital :

Abdominal Hysterectomy



Surgery Notes :

Procedure :	Total Abdominal Hysterectomy
Indication :	
Date of Surgery :	08-Jul-2018

Operative Notes :

Total Abdominal Hysterectomy with Bilateral Salpingectomy

Bladder Catheterized under all aseptic precaution

Patient under spinal anaesthesia

Parts are painted and draped

Previous Scar(If any):

Under all aseptic precaution,

Abdomen opened by tranverse incision

Uterus:

Right Ovary: in size

Left Ovary: in size

POD :

Mobility:

Other Findings (If any): ,

Right Round Ligament with Ligament,clamped, cut, ligated

Left Round Ligament with ligament clamped, cut, ligated

(Bilateral Salpingectomy done)

Bladder: Uterovesical Fold opened,Dissection: Bladder pushed down

Both uterine vessels, skeletanised, clamped,cut and ligated

Uterosacrals,Tranverse ligaments on both sides clamped,cut ligated

D I S C H A R G E S U M M A R Y

Page 2 of 2

Reg. No. :	18926	Date :	15-Sep-2018
Name :	Minal J Kalawadiya]	Age :	31.0
City :		DOA :	01-May-2018
		BG Rh :	
		DOD :	

Vault of vagina,clamped,specimen separated and vault closed
Complete haemostasis confirmed
Mop,Intsrument,Needle count checked and found to be correct
Abdomen closed in layers. Rectus with Polyglycolic acid(Vicryl)
Patient withstood the surgery well. General Condition remained good

Urine output: ml. Appearance: Clear
Post op: Pulse, BP,Respiration normal

Ovary(ies) Removed

Cut Section:

Walls:

Endometrium: